

Neurology
Issue: Volume 53(5), 22 September 1999, pp 974-981
Copyright: Copyright © 1999 American Academy of Neurology
Publication Type: [Articles]
ISSN: 0028-3878
Accession: 00006114-199909220-00016
Keywords: Cerebral hemisphere, Brain morphology, Dyslexia, MRI

[Articles]Previous ArticleTable of ContentsNext Article

The caudal infrasyllvian surface in dyslexia: Novel magnetic resonance imaging-based findings

Green, R. L. MD; Hutsler, J. J. PhD; Loftus, W. C. BS; Tramo, M. J. MD; Thomas, C. E. MA; Silberfarb, A. W. MA; Nordgren, R. E. MD; Nordgren, R. A. MD; Gazzaniga, M. S. PhD

Author Information

From the Departments of Psychiatry (Dr. Green and A.W. Silberfarb) and Pediatrics and Neurology (Dr. Nordgren), Dartmouth Medical School, Lebanon, NH; the Center for Cognitive Neuroscience (Drs. Hutsler, Nordgren, and Gazzaniga, and C.E. Thomas), Dartmouth College, Hanover, NH; the Center for Neuroscience (W.C. Loftus), University of California, Davis, CA; and Department of Neurobiology, Harvard Medical School, Cambridge, and Cognitive/Behavioral Neurology Unit, Massachusetts General Hospital (Dr. Tramo), Boston, MA.

Supported by the National Alliance for Research in Schizophrenia and Depression, Mr. William Martens, Jr., Mr. and Mrs. Robert Boyajian, and Mr. and Mrs. James Winston (R.L.G.); NIH award DC00071 and the McDonnell-Pew Program in Cognitive Neuroscience (M.J.T.); NIH award NS17778 (M.S.G. and J.J.H.), and the Office of Naval Research award N00014-89-J-3035 (M.S.G. and J.J.H.).

Received August 26, 1998. Accepted in final form April 10, 1999.

Address correspondence and reprint requests to Dr. Ronald L. Green, Department of Psychiatry, Dartmouth Medical School, 1 Medical Center Drive, Lebanon, NH 03756.

[Back to Top](#)


Article abstract


Objective: To detect anatomic abnormalities of auditory association cortex in dyslexia by measuring the area of the perisylvian region known as the caudal infrasyllvian surface(s) (cIS) in dyslexic and control subjects.


Background: Several quantitative morphometric investigations of cortical areas in dyslexia have focused on the cIS, which encompasses the supratemporal plane and the inferior bank of the posterior ascending ramus of the sylvian fissure. Inconsistencies in the results of these studies may be attributable in part to the use of measurement methods that do not account fully for surface undulations of the cIS.


Methods: The authors used an MRI-based surface reconstruction technique that models the curvature of the cerebral cortex in three dimensions to obtain whole-hemisphere and regional surface area estimates. Measurements were obtained in both hemispheres of eight right-handed male dyslexic subjects and


Article Tools


- 


Complete Reference
- 


Abstract Reference
-
- 


Print Preview
- 

Email Jumpstart
- 

Email Article Text
- 

Save Article Text
- 

Add to My Projects
- 

Export All Images to PowerPoint
-
- 

Find Similar

About this Journal

Request Permissions

ExternalResolverBasic

Outline

- Article abstract
- References
- IMAGE GALLERY

eight right-handed male control subjects.

Results: The cIS area of dyslexic subjects was significantly larger than that of control subjects, and this result was not attributable to a difference in whole-hemisphere surface area. Neither the dyslexic nor control subjects showed a left or right asymmetry in this region, although there was a trend toward less variance of the asymmetry scores in dyslexic subjects.

Conclusions: The gross anatomic organization of this region is different in dyslexic subjects, and elucidation of the precise nature of these differences may be aided by surface modeling techniques.

To date, 10 in vivo MRI-based investigations of dyslexia have sought to identify anatomic anomalies in the perisylvian region.¹⁻¹⁰ Portions of this region comprise the auditory association cortex, which subserves auditory processes thought to be disturbed in dyslexia.¹¹ Against the benchmark finding in most of the general population of leftward asymmetry of one perisylvian region, the planum temporale (PT),¹² a major focus in neuroanatomic studies of dyslexia has been on PT hemispheric asymmetry patterns. As addressed by Galaburda,¹³ varying approaches to delineating and measuring this region have frustrated comparisons across these studies.

The caudal infrasyllian surface (cIS),¹⁴ a region referred to by Steinmetz et al.¹⁵ as planum plus (the planum plus also includes a very small region-the posterior descending ramus of the sylvian fissure), encompasses the PT and planum parietale (PP).¹⁶ The PP is the surface of the supramarginal gyrus that covers the inferior bank of the posterior ascending ramus (PAR) of the sylvian fissure. In an early cytoarchitectonic study, Galaburda and Sanides¹⁷ noted that area Tpt (temporoparietal), a region of the auditory association cortex, "spills," to varying degrees, from the temporal bank of the PT onto the PP, and, more recently, Witelson et al.¹⁸ reported that cytoarchitectonically identical cortex lines the posterior aspect of the PT and the PP. These observations support combining the PT and PP into one region, the cIS, when attempting to measure the full extent of the auditory association cortex.

To date, five studies have examined the cIS in dyslexia.⁶⁻¹⁰ Two found differences in cIS hemispheric asymmetry patterns or cIS area between control and dyslexic subjects,^{6,9} and three did not.^{7,8,10} Furthermore, among the three studies that showed no cIS differences between dyslexic and control subjects, two found cIS symmetry for both groups^{7,10} and one reported cIS leftward asymmetry for both groups.⁸ These discrepant findings may be attributable in part to the method used to measure surface area, and to the fact that the plane of MRI sections used for measurement varied across studies. The measurement technique used in these previous studies is a standard algorithm, which we have termed the "quasi-three-dimensional (3D) method,"¹⁴ in which contours are drawn across a region of interest as it appears in successive MRI scans. A surface area estimate is obtained by multiplying each contour by the MRI slice thickness, and then summing them.

We have shown previously that the quasi-3D method does not account as fully for cIS area as does another MRI-based technique, the 3D method.¹⁴ This latter method accounts for surface curvature in three dimensions regardless of the MRI plane of section used for measurement. In the 3D technique, surface contours of each hemisphere are used to construct a 3D model of the cerebral cortex. Estimates of the surface area of each hemisphere and its component regions of interest are taken from the model (see the Methods section for a full description of the 3D method).

Given that 1) the use of 3D reconstructions of the cIS yields more accurate measures of the cIS than the quasi-3D method, 2) previous studies of cIS in dyslexia have not relied on a true 3D approach to surface area measurement, and

3) the 3D method provides a reference for assessing the specificity of regional differences by allowing computation of whole-hemisphere surface area, we used the 3D method to compare the area of cIS in dyslexic and control subjects.

Methods. Subjects. We studied eight right-handed male dyslexic Dartmouth College undergraduate and graduate students (age range, 19 to 32 years; mean: 23.5 years) who met Diagnostic and Statistical Manual of Mental Disorders, 4th ed.¹⁹ criteria for developmental reading disorder, but no other disorders. They reported significant difficulties in elementary and secondary school in areas including reading, writing, spelling, learning languages, and recalling names. They compensated sufficiently, however, to graduate high school and matriculate at college.

The results of psychoeducational testing, performed on these subjects by a certified learning disability specialist (AWS), are available from the National Auxilliary Publication Services (NAPS) (see Note at end of article). A diagnosis of dyslexia was based on test results that demonstrated a pattern of deficits in reading rate, writing rate, phonologic awareness, and auditory retrieval that contrasted with superior verbal IQs, in conjunction with their history of significant difficulties learning in school.

All dyslexic subjects were also evaluated by a neurologist (R.E.N.), who performed a neurologic history and physical examination and contacted the mothers of the subjects for additional history. All of the subjects were of normal birth weight. Their mothers had no problems with pregnancy, labor, or delivery, and none of them had any neonatal problems. None of the subjects had any serious illness, and specifically the neurologic review of systems was negative for any conditions such as seizure, stroke-like episodes, complicated migraine, or serious head injuries. One patient reported a mild concussion as a child and another had several mild concussions during high school. Four of the eight reported first-degree relatives with either learning disabilities or reading difficulties. Neurologic examination, including mental status, cranial nerves, and motor, cerebellar, and sensory examination were normal for all subjects, except that one had a mild pupil asymmetry and one had a mild essential tremor. All subjects scored right-handed on the Edinburgh Laterality Quotient ²⁰ (range, 45 to 92; mean, 75).

An age-, handedness-, and educationally matched control sample of eight male students (age range, 19 to 29 years; mean, 24 years) was recruited by advertising among Dartmouth College undergraduate and graduate students. Each control subject was administered the Dartmouth Dyslexia Screening Questionnaire (a semistructured instrument available on request). The questionnaire addresses a wide range of issues related to dyslexia, including queries regarding slow rate of reading or writing; weak spelling and grammar skills; difficulty recalling names; history of poor performance on standardized tests; early history of difficulty learning to read, write, or compute; auditory perceptual deficits (difficulty hearing in a noisy environment; inability to retain oral directions; difficulty learning phonics); slow clerical speed; and a clinical history of specific difficulty with language-associated academic tasks. The control subjects were free of any such history. They were also questioned for any evidence of other neurologic disorders or psychiatric disorders. One control subject had seasonal affective disorder, but the remainder had no history of psychiatric or neurologic disorders. All control subjects scored right-handed on the Edinburgh Laterality Quotient ²⁰ (range, 63 to 92; mean, 75). All subjects in this study gave written informed consent for all procedures.

Image acquisition. T1-weighted MRIs were acquired in the coronal plane (section thickness 3.0 mm, no gap) using a General Electric 1.5-T Signa (Milwaukee, WI) system that yielded 256 × 256 images with an in-plane pixel resolution of either 1.17 or 0.937 mm. Images were obtained using 3D FLASH with TE/TR = 9 milliseconds/50 milliseconds. The head was positioned in the scanner so that a horizontal laser marked the intercanthal line and a vertical laser

intersected the midpoint of the nasion and philtrum. Sagittal sections were imaged (section thickness 5.0 to 8.0 mm, gap, 1.0 mm, in-plane resolution = 1.07 mm) and inspected for rotational tilt by observing whether the rostrum and splenium of the corpus callosum, optic chiasm, and fourth ventricle were evident on the same (mid-sagittal) image. The images were stored on magnetic tape and transferred to a Silicon Graphics (Mountain View, CA) workstation.

Anatomic designations. The dorsal end point of the PAR was chosen as the posterior boundary of the cIS because of the evidence provided by Galaburda and Sanides ¹⁷ and Witelson et al.,¹⁸ which documented extension of the posterior auditory association cortex into the PP. The rostral boundary was that portion of the superior temporal plane just lateral and posterior to the most posterior Heschl's gyrus (HG) on each coronal image on which it is visualized.

No subjects in this study had more than two HG in either hemisphere (of the eight control subjects, one had two HG in the left hemisphere and one had two HG in the right hemisphere. Of the eight dyslexic subjects, two had two HG in the left hemisphere, and two had two HG in the right hemisphere). When two HG were present, we excluded both from cIS measurements, based on von Economo's observation that when there are two HG, the primary auditory cortex spreads over the most anterior HG and partially covers the posterior HG.²¹ The fact that the primary auditory cortex does not fully cover the posterior HG could also be used to justify including the posterior HG in cIS measurements. We could not explore this alternate possibility because our methodology did not permit delineation of the entire boundary of the posterior HG. Specifically, we could not identify the full extent of the sulcus that separates the anterior and posterior HG (i.e., the intermediate sulcus of Beck). As addressed in the Discussion section, we do not believe this limitation compromised this study's conclusions.

We recognize that choice of the anterior boundary of the cIS remains controversial.²² Nonetheless, the issue of excluding the primary auditory cortex from cIS measurement is a fundamental one because primary cortex is involved in auditory functions such as sound localization (for review, see Mesulam ²³), and not the phonologic and other language processes that are disturbed in dyslexia.¹¹

On coronal images, the landmarks of the lateral and medial borders of the cIS vary along their rostral-caudal extents. The lateral border commences anteriorly where the lateral-most aspect of the most posterior HG intersects with the lateral margin of the superior temporal plane. Posterior to this intersection, the lateral border of the cIS continues as the lateral margin of the sylvian fissure and ends posteriorly when the sylvian fissure is no longer visible. In cases where a single HG or a posterior HG did not extend to the lateral margin of the superior temporal plane, the rostral boundary was that portion of the superior temporal plane between its lateral margin and its junction with HG, on the anterior-most image where a single or a posterior HG first appears.

In viewing serial coronal images in an anterior-to-posterior sequence, the anterior aspect of the medial border of the cIS originates, on the first image where HG is no longer visible, at the intersection of the superior temporal plane with the inferior margin of the circular sulcus of the insula. The medial border continues posteriorly in this position until the insula is no longer visible. The medial border then becomes the medial border of the sylvian fissure, and ends when the sylvian fissure is no longer visible.

Image analysis and measurement methods. The image analysis and measurement techniques we used are identical to those used in a previous study.¹⁴ Coronal MRI scans were displayed on a monitor and the pial surface of one hemisphere was manually traced with a cursor. This yielded a contour for every slice in the MRI data set. For each pair of adjacent contours, a mesh of triangles was interpolated across the 3-mm gap between them. The surface reconstruction algorithm used a dynamic programming technique ²⁴ to compute the mesh having minimal surface area. This process was performed for each

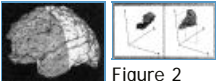


Figure 1

Figure 2

consecutive pair of contours to yield a model of the hemisphere (figure 1). The surface area for the hemisphere and the area of the cIS (figure 2) were quantified by summing the area of the component triangles. This procedure was carried out for both hemispheres.

The reliability of performing regional surface area measurements in this manner was ascertained in the context of an earlier study 25 in which the whole hemisphere and 27 component regions (i.e., the named cortical gyri) were examined. The methods for determining boundaries between regions were reviewed in that study, and interrater and intrarater measures of reliability, in the form of coefficients of variation (CV), were obtained for the whole hemisphere and each region. The CV for hemisphere surface area measurements was 2.7% based on three separate tracings by one rater, and 5.4% based on one tracing by four raters. The interrater and intrarater CVs for individual regions ranged from 3% for the pars triangularis, a readily identifiable region on coronal MRI, to 28% for the superior lateral occipital gyrus, a highly varied and convoluted region. The median CV was 9.4%. Although the cIS was not parceled separately in this earlier study, the MRI landmarks for this region are relatively easy to identify compared with other cortical locations. We expect, therefore, that the CV for the cIS is close to the lower-bound CV of 3% in the previous study, because delineation of the boundaries of the cIS on coronal MRI is as straightforward as delineation of the boundaries of the pars triangularis.

In the current study, two raters were randomly assigned to perform cIS measurements on dyslexic and control subjects. The raters were blind to study hypotheses, and to whether they were rating dyslexic or control subjects.

An asymmetry coefficient was computed for all surface area measurements using the formula $(L - R)/(0.5 \times [L + R])$, where R and L are the surface areas (in square centimeters) of the right and left homologues, respectively. In accordance with previous studies (e.g., Galaburda et al.26), a structure with a coefficient magnitude of 0.100 or greater was classified as asymmetric, with a positive value indicating leftward asymmetry, and a negative value indicating rightward asymmetry.

Data analysis. To determine if the distribution of cortical surface area differs between control and dyslexic subjects, measurements of each hemisphere and each cIS were made for every subject. From these initial measures, we also calculated cIS areas that were normalized for hemisphere surface area. We also computed hemispheric asymmetry coefficients, and asymmetry coefficients for the cIS.

Surface area measures of the hemispheres and the cIS were first subjected to univariate analyses of variance with subject group (control versus dyslexic subjects) treated as a between-groups factor and hemisphere (left versus right) treated as a repeated measure. Asymmetry scores of the two groups were compared with each other using *t*-tests for two means and were also compared with symmetry (zero) using *t*-tests for single means. Differences in the distribution of the asymmetry scores between the two groups were assessed by comparing their absolute magnitudes using a *t*-test for two means, and by testing directly for homogeneity of variance between the two groups using Levene's test.

Results. *Cortical surface area differences between dyslexic and control subjects.* Table 1 displays cIS and hemisphere surface area measurements for all subjects. A comparison of the two subject groups revealed no difference between the whole-brain surface areas of dyslexic subjects (mean = 1700.75 ± 47.37 mm²) and control subjects (mean = 1603.58 ± 51.31 mm², *p* = 0.19). Analysis of the hemisphere surface area measurements revealed no differences between the left and right hemispheres (*p* = 0.46) and no interaction between subject group and hemisphere (*p* = 0.19; figure 3A).

Table 1



Figure 3

A comparison of the area of the cIS showed a significant difference between dyslexic and control subjects ($p = 0.02$), but no difference between the hemispheres ($p = 0.61$) and no interaction ($p = 0.61$; figure 3B). The cIS surface area difference between dyslexic and control subjects was not attributable to overall differences in brain size because the pattern of results was unchanged if the area of the cIS was normalized to the total surface area of the hemisphere in which it resides by expressing its value as a percentage of the hemisphere surface area (subject group: $p = 0.01$; hemisphere: $p = 0.35$; subject group \times hemisphere: $p = 0.778$).

Asymmetry scores. Table 2 lists cIS and hemisphere asymmetry coefficients for all subjects. Asymmetry coefficients for the cIS of all the subjects did not differ significantly from zero (mean = -0.0633 , $t = -0.81$, $df = 15$, $p = 0.43$). The average asymmetry coefficients for control subjects (mean = -0.0977 , $t = -0.65$, $df = 7$, $p = 0.54$) and dyslexic subjects (mean = -0.0289 , $t = -0.54$, $df = 7$, $p = 0.60$) also did not differ appreciably from zero. In addition, these asymmetry coefficients did not differ between the two groups ($t = -0.43$, $df = 14$, $p = 0.67$). Coefficients generated for the whole hemispheres also showed no asymmetries for control subjects (mean = -0.0164 , $t = -1.37$, $df = 7$, $p = 0.21$) or dyslexic subjects (mean = 0.0048 , $t = 0.68$, $df = 7$, $p = 0.52$), as well as no difference between the mean asymmetry scores of the two groups ($t = -1.52$, $df = 14$, $p = 0.15$). Thus, both the cIS and the hemispheres are symmetric when asymmetry coefficients are averaged across subjects.



Table 2

Homogeneity of variance. Although the mean cIS asymmetry coefficients did not differ between control and dyslexic subjects, control subjects showed a trend toward greater variance in their asymmetry coefficients (Levene's = 4.175 , $p = 0.06$). In contrast, the variance of the overall hemispheric asymmetry coefficients did not differ significantly between dyslexic and control subjects (Levene's = 2.665 , $p = 0.12$). The range of asymmetry scores was broader in control subjects (-0.568 to 0.753) than dyslexic subjects (-0.204 to 0.208), and four of the control subjects had marked asymmetry (-0.568 , -0.471 , -0.462 , and -0.753). This effect was also apparent when the absolute magnitude (i.e., direction of asymmetry ignored) of the asymmetry coefficients were considered. Dyslexic subjects had significantly lower absolute asymmetry scores (mean = 0.129 ± 0.064) than control subjects (mean = 0.342 ± 0.064 , $t = 2.368$, $df = 14$, $p = 0.03$; figure 4). Although several of our control subjects did not show a prominent asymmetry in the cIS, these results indicate that as a group, control subjects may have a greater degree of cIS asymmetry compared with dyslexic subjects, but no preferred direction of asymmetry.



Figure 4

Discussion. In this study, dyslexic and control subjects had overall cIS symmetry, a result consistent with that of Leonard et al.⁷ and Rumsey et al.,¹⁰ and approximate to that of Gauger et al.⁹ who found that control subjects had a symmetric cIS and that dyslexic subjects had only slight rightward asymmetry. We suggest that the concordance of these four studies may be due largely to the ability of their respective methodologies to account for the surface of the PAR. In the three previous studies,^{7,9,10} measurement of the PAR may have been optimized by the use of sagittal images that capture the obliquity of the PAR surface with respect to the coronal plane; in the current study, this was achieved by reconstructing this tilted surface from a sequence of coronal images.

In contrast to the current study, Larsen et al.⁶ found that the cIS was more commonly leftward asymmetric in control subjects (70%) than dyslexic subjects (30%), and Schultz et al.⁸ reported that 70% of both dyslexic and control subjects had a leftward-asymmetric cIS. These two studies used coronal MRIs in conjunction with the quasi-3D method. This combination results in foreshortened measures of the cIS, a problem which is more acute in the right hemisphere where the PAR makes up a larger proportion of the cIS surface.¹⁴ Therefore, we speculate that the discordance of the current findings with those of Larsen et al.⁶ and Schultz et al.⁸ is due to spurious findings of leftward asymmetry in the latter.

In addition to avoiding anteroposterior foreshortening of the PAR, the 3D method also accounts for surface curvatures in the other two orthogonal dimensions. None of the measurement methods used in the five prior studies of the cIS in dyslexia 6-10 accomplishes this. The one study that used a surface rendering technique to model the PT portion of cIS 10 used a two-dimensional technique for surface measurement.

The use of 3D methodology, which has now been adopted in other investigations,22,27,28 may explain two novel findings in the current study. First, the cIS area of dyslexic subjects was significantly larger than that of control subjects. Whole-hemisphere surface area of dyslexic subjects was not significantly larger than in control subjects, and, in a prior study examining lobar surface area in the same dyslexic and control subjects as in the current study, we found no significant differences in left or right whole temporal or parietal lobe surface areas between the groups.29 In addition, in the current study, normalizing the area of the cIS to whole-hemisphere surface area did not change this result. Therefore, the larger cIS of dyslexic subjects in this study was not a consequence of larger temporal lobes, parietal lobes, or hemispheres. Larger cIS measures in dyslexia could either be the result of more exuberant growth of neuropil or the addition of cortical columns, or larger regions could result from less involution in the course of corticogenesis. Studies by Galaburda et al.26,30 support the latter possibility.

Barta et al.28 recently reported that the surface area of the right hemisphere temporal bank of cIS (i.e., PT) is larger in schizophrenia, another disorder associated with language-related symptoms and possible neurodevelopmental origins.31 In the schizophrenia cohort of Barta et al.,28 however, the volume of the right PT was also reduced, indicating thinning of the cortical ribbon. To our knowledge, cortical thinning has not been assessed in dyslexia.

The study's second finding was that although the mean asymmetry coefficient for the cIS in control and dyslexic subjects indicated no directional asymmetry, the dyslexic subjects had a significantly smaller mean absolute magnitude of asymmetry and showed a trend toward less variable asymmetry scores than control subjects. This effect was apparent in the markedly narrower range of asymmetry scores in the dyslexic subjects. To the extent that normal reading facility may correlate with a genetically based capacity to specify greater range (leftward as well as rightward), variability, and absolute magnitude of cIS asymmetry than is present in dyslexic subjects, the current findings resonate with observations that mice can be bred for strength of pawedness but not which paw, left or right, will become stronger,32 and with the suggestion of Habib et al.33 that degree of handedness and not its direction determines the relationship of handedness to planum asymmetry patterns.

The cIS differences we have identified in dyslexia may be part of a broader pattern of cortical and subcortical disturbances in this disorder. Functional disturbances have been implicated in all four cortical lobes in dyslexia,11,34 and abnormalities have been identified in the medial geniculate body.35 These abnormalities may suggest perturbed neurodevelopment responsible for widespread brain differences between dyslexic subjects and unimpaired people. A similar story is unfolding in schizophrenia.31

It is important to consider whether morphometric differences between dyslexic and control subjects are epiphenomena, not related to disturbances in reading ability. A functional MRI study by Binder et al.36 raises this possibility by demonstrating that the region of the PT was activated by tones and words, whereas the region encompassing the superior temporal sulcus, which divides the superior temporal gyrus from the middle temporal gyrus, had a larger activation by words relative to tones. The superior temporal sulcus region has not been measured specifically in dyslexia except indirectly by whole temporal lobe measurements.8,29 This finding and similar findings in other functional imaging studies sound a cautionary note that should be heeded in efforts to interpret the significance of regional cortical measurements in dyslexia.

Although much emphasis has been placed on the importance of regional size differences between the two hemispheres, recent evidence indicates that functional specializations for language may also be due, in part, to differences in the microanatomic organization of these regions. Language-related cortical areas show significant differences in the organization of intracortical connectivity [37](#) and in the structure of layer III pyramidal cells.[38](#) In addition, the distribution of neuroactive substance may also vary between homotopic cortical regions that are functionally distinct.[39](#) Much remains to be studied regarding other aspects of microanatomic cortical organization and how these regional differences relate to specification of cortical regions and the performance of cortically mediated behaviors (see Hutsler and Gazzaniga [40](#) for a review).

The current study raises several methodologic issues. The first is our exclusion of a second HG from cIS measurements. Barta et al.,[22](#) in a review of the literature on this issue, concluded that additional HG should be included in measures of the PT. As we pointed out earlier, however, the cytoarchitectonic studies of von Economo [21](#) reported that primary auditory cortex "partly covers" a second HG when present, justifying its exclusion from cIS measurements. It is unlikely that our asymmetry findings would have been altered by including a second HG in the cIS because both dyslexic and control subjects in the current study had equal numbers of HG in both hemispheres.

Second, because we did not obtain serial sagittal images, we were unable to parse the cIS into the PT and PP. Therefore, we cannot comment on whether the study findings might have been related more to differences in one of these subdivisions than the other, or on whether additional differences between control and dyslexic subjects would have emerged had the PT and PP been measured separately.

Third, our use of univariate tests to compare both the overall surface area of the hemispheres, as well as a subcomponent of each hemisphere (the cIS), may result in an inaccurate assessment of differences in cortical surface area between the two groups because these measures are intercorrelated. The *p* value that demonstrated the difference between the two groups was not adjusted for multiple testing. The finding requires replication by a study designed specifically to address this issue.

Finally, our findings are tempered by the nature of our subject pool. Our conclusions are confined to right-handed male college students with dyslexia, so they may not be applicable to women, those with mixed or left handedness, or dyslexic people who do not seek a college education. Furthermore, an increased sample size could demonstrate other differences between the two groups that we were unable to detect.

Note. Readers can obtain 3 pages of supplementary material from the National Auxiliary Publications Service, 248 Hempstead Turnpike, West Hempstead, NY 11552. Request document no. 05508. Remit with your order, not under separate cover, in US funds only, \$15.00 for photocopies or \$5.00 for microfiche. Outside the United States and Canada, add postage of \$4.50 for the first 20 pages and \$1.00 for each 10 pages thereafter, or \$5.00 for the first microfiche and \$1.00 for each fiche thereafter. *There is a \$25.00 invoicing charge on all orders filled before payment.*

[Back to Top](#)

References

1. Hynd GW, Semrud-Clikeman M, Lorys AR, Novey ES, Eliopoulos D. Brain morphology in developmental dyslexia and attention deficit disorder/hyperactivity.

Arch Neurol 1990;47:919-926. [Bibliographic Links](#) | [\[Context Link\]](#)

2. Duara R, Kushch A, Gross-Glenn K, et al. Neuroanatomic differences between dyslexic and normal readers on magnetic resonance imaging scans. Arch Neurol 1991;48:410-416. [\[Context Link\]](#)

3. Plante E, Swisher L, Vance R. MRI findings in boys with specific language impairment. Brain Lang 1991;41:52-66. [\[Context Link\]](#)

4. Jernigan TL, Hesselink JR, Sowell E, Tallal PA. Cerebral structure on magnetic resonance imaging in language- and learning-impaired children. Arch Neurol 1991;48:539-545. [Bibliographic Links](#) | [\[Context Link\]](#)

5. Kushch A, Gross-Glenn K, Jallad B, et al. Temporal lobe surface area measurements on MRI in normal and dyslexic readers. Neuropsychologia 1993;31:811-821. [Bibliographic Links](#) | [\[Context Link\]](#)

6. Larsen JP, Høien T, Lundberg I, Odegaard H. MRI evaluation of the size and symmetry of the planum temporale in adolescents with developmental dyslexia. Brain Lang 1990;39:289-301. [\[Context Link\]](#)

7. Leonard CM, Voeller KKS, Lombardino LJ, et al. Anomalous cerebral structure in dyslexia revealed with magnetic resonance imaging. Arch Neurol 1993;50:461-469. [Bibliographic Links](#) | [\[Context Link\]](#)

8. Schultz RT, Cho NK, Staib LH, et al. Brain morphology in normal and dyslexic children: the influence of sex and age. Ann Neurol 1994;35:732-742. [Bibliographic Links](#) | [\[Context Link\]](#)

9. Gauger LM, Lombardino LJ, Leonard CM. Brain morphology in children with specific language impairment. J Speech Lang Hear Res 1997;40:1272-1284. [\[Context Link\]](#)

10. Rumsey JM, Donohue BC, Brady DR, Nace K, Giedd JN, Andreason P. A magnetic resonance imaging study of planum temporale asymmetry in men with developmental dyslexia. Arch Neurol 1997;54:1481-1489. [Bibliographic Links](#) | [\[Context Link\]](#)

11. Shaywitz SE, Shaywitz BA, Pugh KR, et al. Functional disruption in the organization of the brain for reading in dyslexia. Proc Natl Acad Sci USA 1998;95:2636-2641. [Bibliographic Links](#) | [\[Context Link\]](#)

12. Geschwind N, Levitsky W. Human brain: left-right asymmetries in the temporal speech region. Science 1968;161:186-187. [Bibliographic Links](#) | [\[Context Link\]](#)

13. Galaburda AM. The planum temporale. Arch Neurol 1993;50:457. Editorial. [\[Context Link\]](#)

14. Loftus WC, Tramo MJ, Thomas CE, Green RL, Nordgren RA, Gazzaniga MS. Three-dimensional quantitative analysis of hemispheric asymmetry in the human superior temporal region. Cereb Cortex 1993;3:348-355. [Bibliographic Links](#) | [\[Context Link\]](#)

15. Steinmetz H, Rademacher J, Jäncke L, Huang Y, Thron A, Zilles K. Total surface of temporoparietal intrasyllian cortex: diverging left-right asymmetries. Brain Lang 1990;39:357-372. [\[Context Link\]](#)

16. Jäncke L, Schlaug G, Huang Y, Steinmetz H. Asymmetry of the planum parietale. Neuroreport 1994;5:1161-1163. [Ovid Full Text](#) | [Bibliographic Links](#) | [\[Context Link\]](#)

17. Galaburda AM, Sanides F. Cytoarchitectonic organization of the human auditory cortex. J Comp Neurol 1980;190:597-610. [Bibliographic Links](#) | [\[Context Link\]](#)

18. Witelson SF, Glezer II, Kigar DL. Women have greater density of neurons in posterior temporal cortex. J Neurosci 1995;15:3418-3428. [Bibliographic Links](#) | [\[Context Link\]](#)

19. American Psychiatric Association. Diagnostic and statistical manual of mental disorders. 4th ed. Washington, DC: American Psychiatric Association Press, 1994. [\[Context Link\]](#)

20. Oldfield RC. The assessment and analysis of handedness: the Edinburgh Inventory. Neuropsychologia 1971;9:97-113. [Bibliographic Links](#) | [\[Context Link\]](#)

21. von Economo C. The cytoarchitectonics of the human cerebral cortex. Oxford: Oxford University Press, 1929:116. [\[Context Link\]](#)

22. Barta PE, Petty RG, McGilchrist I, et al. Asymmetry of the planum temporale: methodological considerations and clinical associations. Psychiatry Res 1995;61:137-150. [Bibliographic Links](#) | [\[Context Link\]](#)

23. Mesulam MM. Patterns in behavioral neuroanatomy: association areas, the limbic system, and hemispheric specialization. In: Principles of behavioral neurology. Philadelphia: FA Davis, 1985:19-22. [\[Context Link\]](#)

24. Cormen TH, Leiserson CE, Rivest RL. Introduction to algorithms. Cambridge, MA: MIT Press, 1990. [\[Context Link\]](#)

25. Tramo MJ, Loftus WC, Thomas CE, et al. Surface area of human cerebral cortex and its gross morphological subdivisions: in vivo measurements in monozygotic twins suggest differential hemispheric effects of genetic factors. Journal of Cognitive Neuroscience 1995;7:292-302. [\[Context Link\]](#)

26. Galaburda AM, Corsiglia J, Rosen GD, Sherman GF. Planum temporale asymmetry: reappraisal since Geschwind and Levitsky. Neuropsychologia 1987;25:853-868. [Bibliographic Links](#) | [\[Context Link\]](#)

27. Petty RG, Barta PE, Pearson GD, et al. Reversal of asymmetry of the planum temporale in schizophrenia. Am J Psychiatry 1995;152:715-721. [Bibliographic Links](#) | [\[Context Link\]](#)

28. Barta PE, Pearson GD, Brill LB, et al. Planum temporale asymmetry reversal in schizophrenia: replication and relationship to gray matter abnormalities. Am J Psychiatry 1997;154:661-667. [Bibliographic Links](#) | [\[Context Link\]](#)

29. Loftus WC, Tramo MJ, Gazzaniga MS. Cortical surface modeling reveals gross morphometric correlates of individual differences. Human Brain Mapping 1995;3:257-270. [Bibliographic Links](#) | [\[Context Link\]](#)

30. Galaburda AM, Sherman GF, Rosen GD, Aboitiz F, Geschwind N. Developmental dyslexia: four consecutive patients with cortical abnormalities. Ann Neurol 1985;18:222-233. [Bibliographic Links](#) | [\[Context Link\]](#)

31. Weinberger DR, Lipska BK. Cortical maldevelopment, anti-psychotic drugs, and schizophrenia: a search for common ground. Schizophr Res 1995;16:87-110. [Bibliographic Links](#) | [\[Context Link\]](#)

32. Collins RL. Reimpressed selective breeding for lateralization of handedness in mice. Brain Res 1991;564:194-202. [Bibliographic Links](#) | [\[Context Link\]](#)

33. Habib M, Robichon F, Levrier K, Salamon G. Diverging asymmetries of temporo-parietal cortical areas: a reappraisal of Geschwind/Galaburda theory. Brain Lang 1995;48:238-258. [\[Context Link\]](#)

34. Salmelin R, Service E, Kiesilä P, Uutela K, Salonen O. Impaired visual word processing in dyslexia revealed with magnetoencephalography. Ann Neurol 1996;40:157-162. [Bibliographic Links](#) | [\[Context Link\]](#)

35. Galaburda AM, Eidelberg D. Symmetry and asymmetry in the human posterior thalamus: II. thalamic lesions in a case of developmental dyslexia. Arch Neurol 1982;39:333-336. [Bibliographic Links](#) | [\[Context Link\]](#)

36. Binder JR, Frost JA, Hammeke TA, Rao SM, Cox RW. Function of the left planum temporale in auditory and linguistic processing. Brain 1996;119:1239-1247. [Bibliographic Links](#) | [\[Context Link\]](#)

37. Galuske RAW, Schlote W, Singer W. Interhemispheric differences of patchy intrinsic connections in Wernicke's area (area 22) of the human brain. Society for Neuroscience 1995;25:675. Abstract. [\[Context Link\]](#)

38. Hayes TL, Lewis DA. Anatomical specialization of the anterior motor speech area: hemispheric differences in magnopyramidal neurons. Brain Lang 1995;49:289-308. [\[Context Link\]](#)

39. Hutsler JJ, Gazzaniga MS. Hemispheric differences in the density of parvalbumin-containing interneurons are found within language-associated regions of the human cerebral cortex. Society for Cognitive Neuroscience 1995;2:181. Abstract. [\[Context Link\]](#)

40. Hutsler JJ, Gazzaniga MS. The organization of human language cortex: special adaptation or common cortical design. The Neuroscientist 1997;3:367-378. [\[Context Link\]](#)

Key words: Cerebral hemisphere; Brain morphology; Dyslexia; MRI

IMAGE GALLERY

Select All

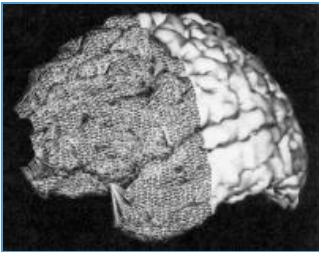


Figure 1

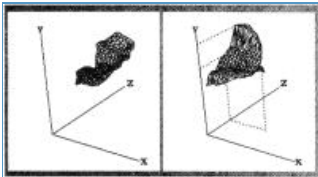


Figure 2

Subjects	Left	Right
Control		
1	6.29 (696.10)	2.85 (699.49)
2	4.22 (756.60)	6.82 (778.43)
3	6.01 (804.10)	7.44 (826.29)
4	3.11 (722.82)	5.58 (762.04)
5	6.33 (873.12)	5.56 (844.55)
6	6.97 (758.11)	7.73 (810.54)
7	5.13 (814.95)	4.67 (813.68)
8	6.55 (940.63)	9.85 (927.15)
Mean	5.58 (795.80)	6.31 (807.37)
SD	1.32 (80.72)	2.13 (86.19)
Dyslexic		
1	-5.64 (762.79)	6.43 (766.86)
2	7.02 (906.52)	6.91 (917.47)
3	8.48 (881.88)	10.41 (903.73)
4	6.50 (766.23)	7.05 (755.37)
5	9.92 (933.49)	10.78 (936.79)
6	8.49 (898.79)	6.89 (881.94)
7	7.87 (836.61)	6.59 (814.90)
8	7.34 (825.71)	8.38 (796.94)
Mean	7.66 (851.50)	7.93 (848.00)
SD	1.33 (64.29)	1.75 (72.34)

* Hemispheric measures appear in parentheses.

Table 1

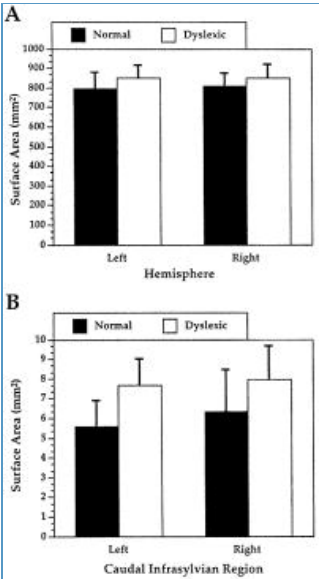


Figure 3

Subjects	cIS Asymmetry	Hemisphere asymmetry
Control		
1	0.753	-0.005
2	-0.471	-0.028
3	-0.213	-0.027
4	-0.568	-0.053
5	0.130	0.033
6	-0.103	-0.067
7	0.094	0.002
8	-0.402	0.014
Dyslexic		
1	-0.131	-0.005
2	0.017	-0.012
3	-0.204	-0.024
4	-0.081	0.014
5	-0.083	-0.004
6	0.208	0.008
7	0.177	0.026
8	-0.132	0.035

* A minus sign denotes rightward asymmetry.
cIS = caudal infrasyllvian surface.

Table 2

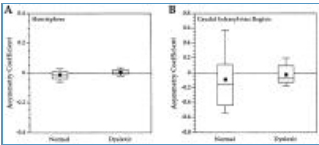


Figure 4

[Previous Article](#) | [Table of Contents](#) | [Next Article](#)